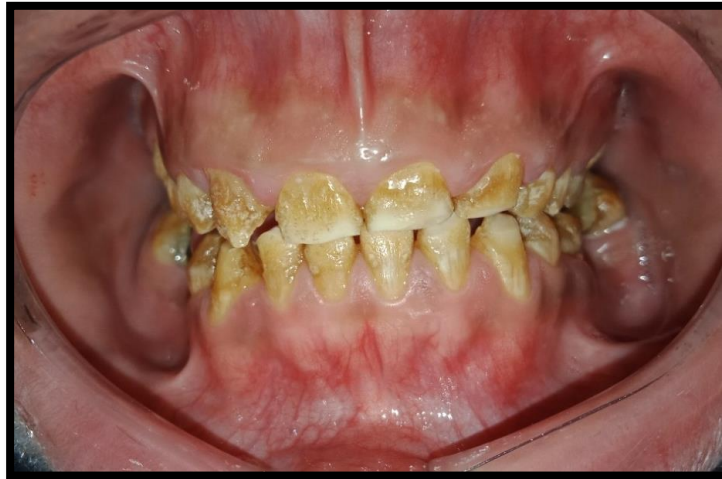

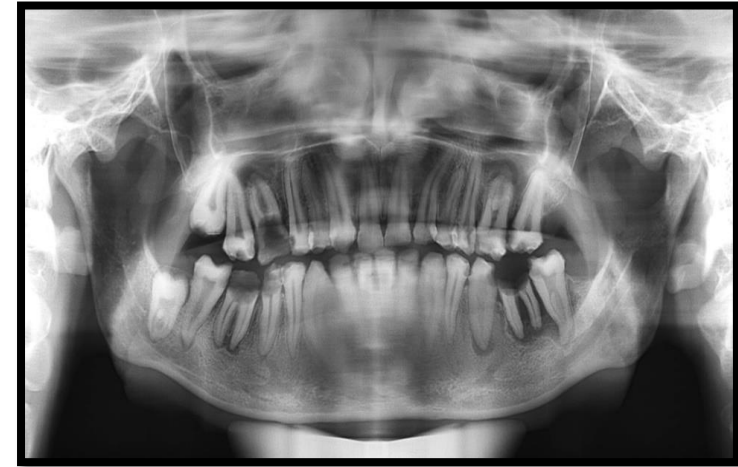CASE 2- Full mouth rehabilitation of case with amelogenesis imperfecta



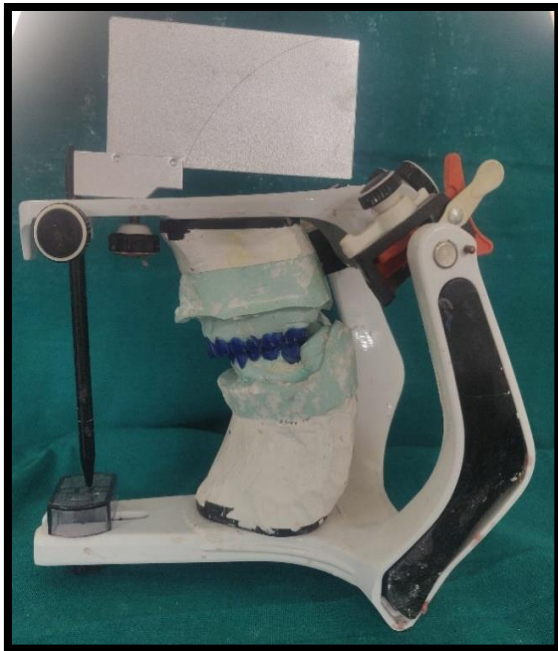Pre-op portrait image



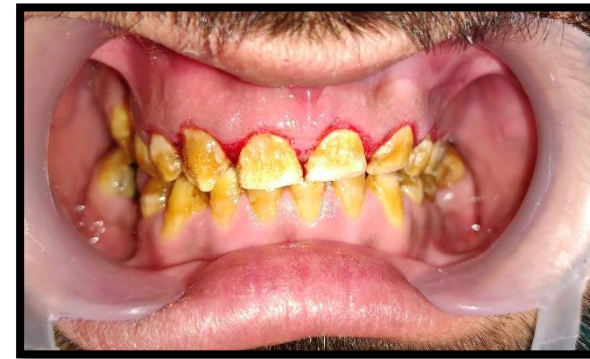Pre-op Intra-oral view



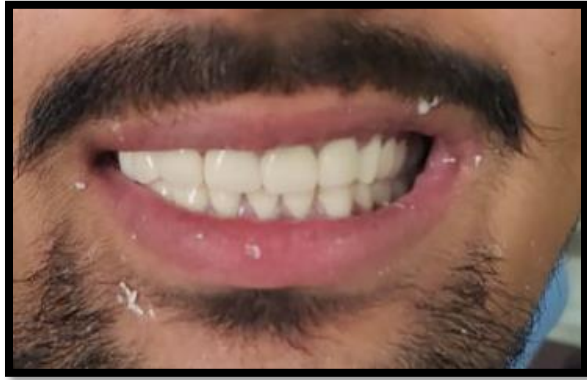Pre-op O.P.G



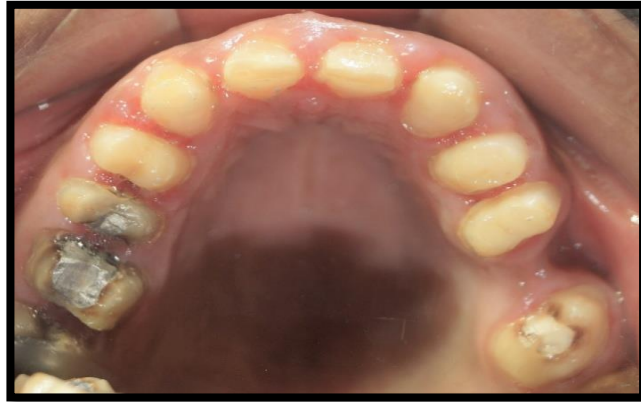Wax-mock up using Broadrick flag analyzer



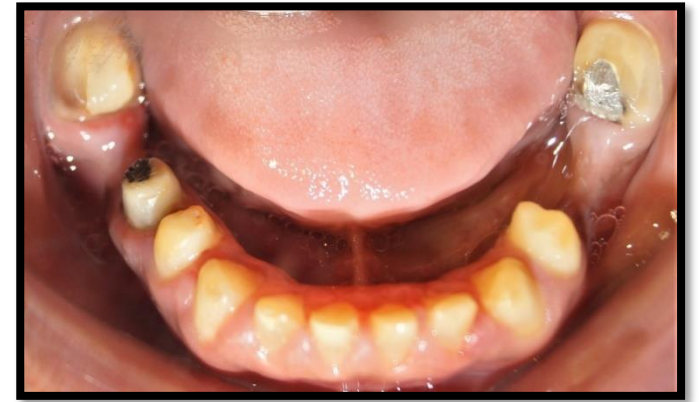Gingivectomy performed according to wax-up



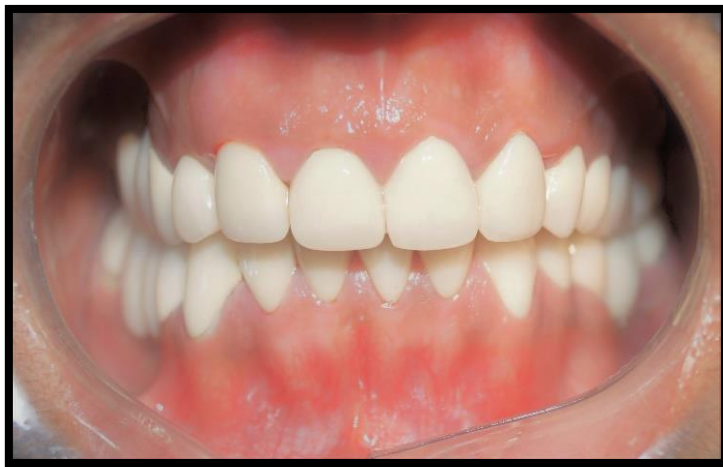*Temporization done with bis-acrylate
follow-up for 8 weeks*




*Tooth preparation done
(maxillary)*



*Tooth preparation done
(mandibular)*



Post-op intraoral view



Post-op Portrait